

# Guidelines for the management of traumatic dental injuries. III. Primary teeth

Flores MT, Malmgren B, Andersson L, Andreasen JO, Bakland LK, Barnett F, Bourguignon C, DiAngelis A, Hicks L, Sigurdsson A, Trope M, Tsukiboshi M, von Arx T. Guidelines for the management of traumatic dental injuries. III. Primary teeth. *Dent Traumatol* 2007. © Blackwell Munksgaard, 2007

**Abstract** – Trauma to the primary dentition present special problems and the management is often different as compared with permanent teeth. An appropriate emergency treatment plan is important for a good prognosis. Guidelines are useful for delivering the best care possible in an efficient manner. The International Association of Dental Traumatology (IADT) has developed a consensus statement after a review of the dental literature and group discussions. Experienced researchers and clinicians from various specialties were included in the group. In cases in which the data did not appear conclusive, recommendations were based on the consensus opinion of the IADT board members. The guidelines represent the current best evidence based on literature research and professional opinion. In this third article out of three, the IADT Guidelines for the management of traumatic injuries in the primary dentition, are presented.

**Marie Therese Flores<sup>1</sup>, Barbro Malmgren<sup>2</sup>, Lars Andersson<sup>3</sup>, Jens Ove Andreasen<sup>4</sup>, Leif K. Bakland<sup>5</sup>, Frederick Barnett<sup>6</sup>, Cecilia Bourguignon<sup>7</sup>, Anthony DiAngelis<sup>8</sup>, Lamar Hicks<sup>9</sup>, Asgeir Sigurdsson<sup>10</sup>, Martin Trope<sup>11</sup>, Mitsuhiro Tsukiboshi<sup>12</sup>, Thomas von Arx<sup>13</sup>**

<sup>1</sup>Pediatric Dentistry, Faculty of Dentistry, University of Valparaiso, Valparaiso, Chile; <sup>2</sup>Department of Pediatrics, Karolinska Institute, Huddinge, Sweden; <sup>3</sup>Oral & Maxillofacial Surgery, Faculty of Dentistry, Kuwait University, Safat, Kuwait; <sup>4</sup>Department of Oral and Maxillofacial surgery, University Hospital, Copenhagen, Denmark; <sup>5</sup>Endodontics, School of Dentistry, Loma Linda University, Loma Linda, CA, USA; <sup>6</sup>Albert Einstein Medical Center, Philadelphia, PA, USA; <sup>7</sup>Private Practice, Paris, France; <sup>8</sup>Hennepin County Medical Center, Minneapolis, MN, USA; <sup>9</sup>Endodontics, University of Maryland, Baltimore, MD, USA; <sup>10</sup>Private Practice, Reykjavik, Iceland; <sup>11</sup>Endodontics, University of North Carolina, Chapel Hill, NC, USA; <sup>12</sup>Private Practice, Nagoya, Japan; <sup>13</sup>Oral Surgery and Stomatology, University of Berne, Berne, Switzerland

**Key words:** trauma; tooth; deciduous; preschool children; injury; periodontal; emergency; consensus; review

Marie Therese Flores, The International Association of Dental Traumatology, PO Box 1057, Loma Linda, CA 92354, USA  
Tel.: +56 32 250 8690  
<http://www.iadt-dentaltrauma.org>  
e-mail: [mariateresa.flores@uv.cl](mailto:mariateresa.flores@uv.cl)

Trauma to the oral region occurs frequently and comprises 5% of all injuries for which people seek treatment (1–4). In preschool injuries, head injuries make up as much as 40% of all somatic injuries (1–4). Among all facial injuries, dental injuries are the most common (1–4). As much as 18% of all somatic injuries are seen in the oral region in children 0–6 years old (1–4).

An appropriate treatment plan after an injury is important for a good prognosis. Guidelines are useful for dentists and other healthcare professionals in delivering the best care possible in an efficient manner. The International Association of Dental Traumatology (IADT) has developed a consensus statement after a review of the dental literature and group discussions. Experienced researchers and

clinicians from various specialties were included in the group. In cases in which the data did not appear conclusive, recommendations were based on the consensus opinion of the IADT board members. The guidelines represent the current best evidence based on literature research and professional opinion. As is true for all guidelines, the healthcare provider must apply clinical judgment dictated by the conditions present in the given traumatic situation. The IADT does not guarantee favorable outcomes from following the Guidelines, but using the recommended procedures can maximize the chances of success. Because management of permanent and primary dentition differs significantly, separate guidelines for management of permanent and primary teeth have been developed. Updating the Guidelines is an ongoing process, and the Guidelines are available on the IADT web page <http://www.iadt-dentaltrauma.org>. In addition to the clinical guidelines, there is also a forum for discussion on this web page and a possibility to download information material for professionals and the public.

The publication of the IADT guidelines in the journal *Dental Traumatology* has been divided into three parts

*Part I: Crown fractures and luxations of permanent teeth* in *Dental Traumatology* issue 2; 2007

*Part II. Avulsion of permanent teeth* in issue 3; 2007

*Part III. Guidelines for the management of traumatic injuries in the primary dentition* published in this issue.

### First aid and treatment of trauma to the primary dentition

Depending on the severity of injuries, usually, the parents will seek treatment at the Emergency Room or will call the pediatrician. Dentists should be willing to give appropriate advice to healthcare professionals and those who closely work or supervise children, about first aid for injuries affecting the primary dentition.<sup>(5, 6)</sup>

The following recommendations will help for the best care of the child:

Keep calm and concentrate in the child well-being.

Wash the wound carefully with plenty of running water. Generally, dental trauma includes injuries to the adjacent soft tissue (Fig 1).

Stop bleeding by compressing the injured area with gauze or cotton for 5 min.

Seek emergency treatment from a pediatric dentist.

### Guidelines for the Emergency Room

In more severe injuries, especially, when there is bleeding of the lips and intra-oral soft tissue, the

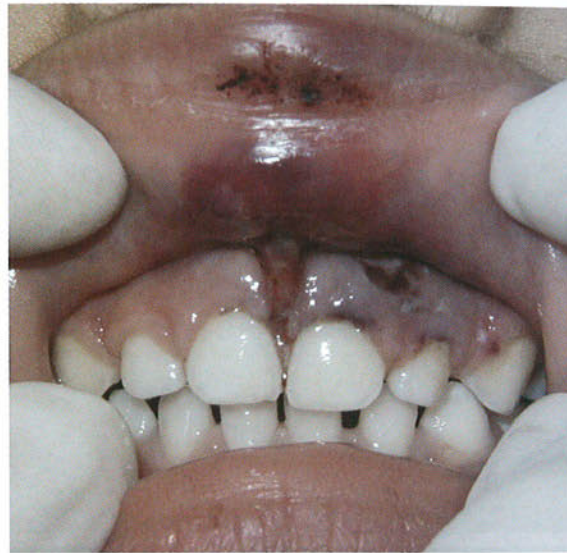

Fig. 1. Soft tissue injuries of the upper lip and torn frenum.

parents will seek treatment at the Emergency Room where physicians will give the first treatment (Fig 2).

After suture of soft tissue lacerations, the child should be referred to a pediatric dentist or a general dentist who treats children for a general evaluation of teeth injuries.

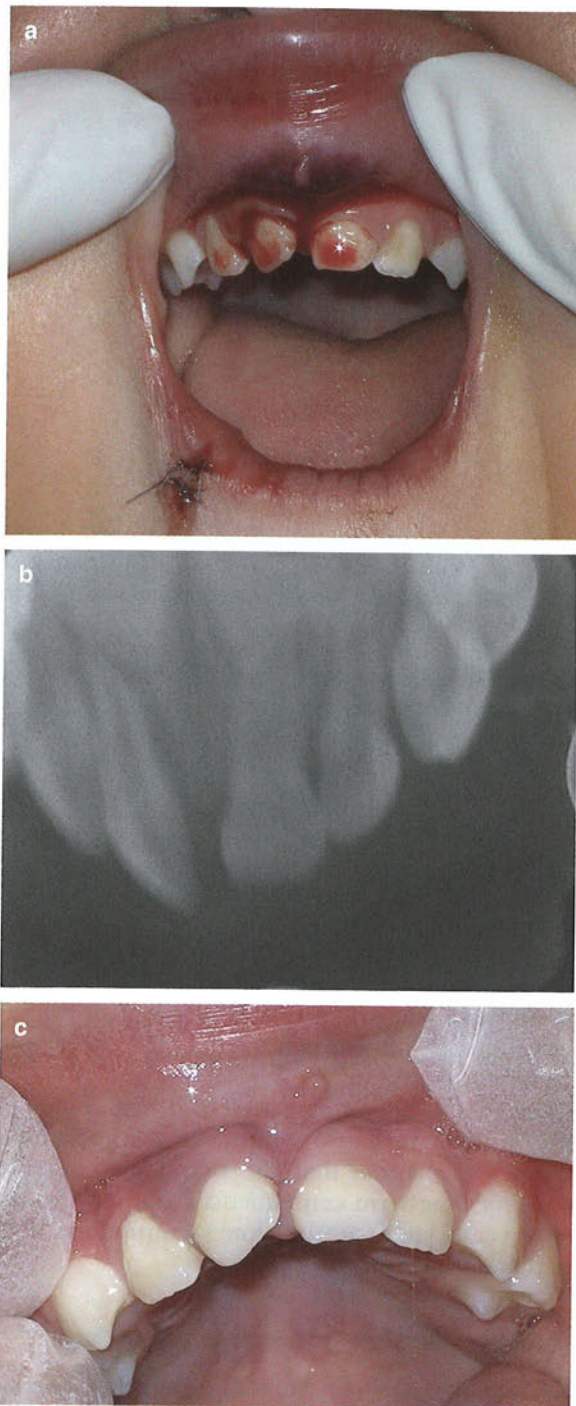
Intra-oral trauma affecting the lips, gums, tongue, palate, and severe tooth injuries in children <5 years old, should be examined and suspect of child abuse (7–9). In such cases, the patient should also be examined by a pediatric dentist on call or oral surgeon who will give the diagnosis of primary teeth injuries and prognosis for the developing permanent dentition.

The child should be referred for follow-up controls to a pediatric dentist. It is important to explain the parents that the permanent dentition may have long-term consequences that may be seen many years later, at the time of eruption of the permanent incisors.

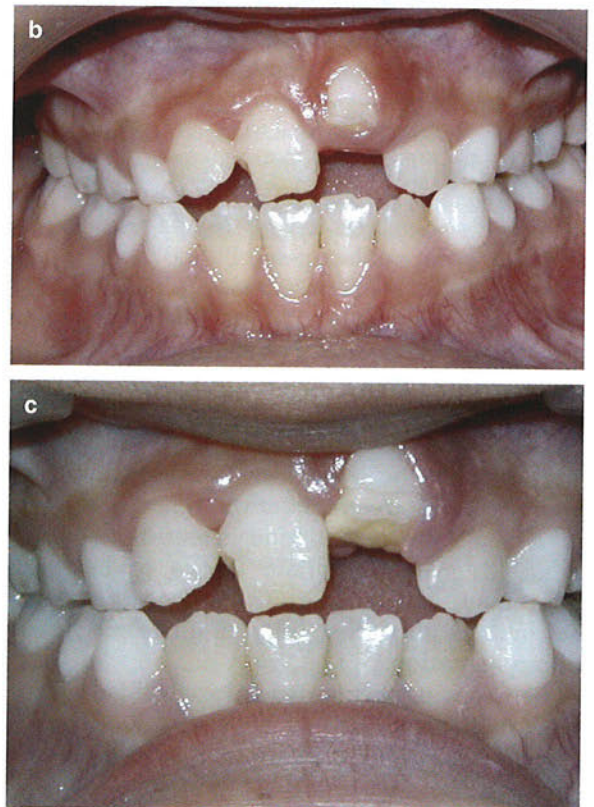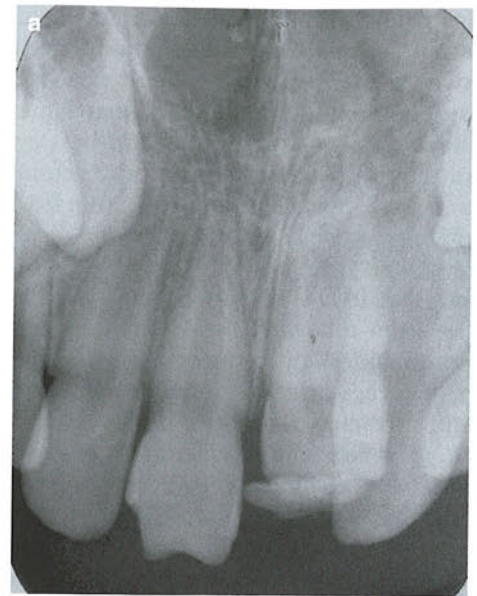### Special considerations for trauma to primary teeth

The management of traumatic injuries to primary teeth differs from that used for permanent.

It is important to keep in mind that there is close relationship between the apex of the root of the injured primary tooth and the underlying permanent tooth germ. Tooth malformation, impacted teeth and eruption disturbances in the developing permanent dentition are some of the consequences that can occur following severe injuries to primary teeth and/or alveolar bone (Fig 3). Because of these potential sequelae, treatment selection should such as to avoid any additional risks of further damaging the permanent successors.



*Fig. 2.* Acute trauma to oral soft tissues and primary teeth. A 2-year-old girl fell on the floor. Suture of the lower lip laceration was the immediate treatment carried out at the Emergency Room and antibiotics were prescribed. The patient was referred to a pediatric dentist. (a) Bleeding from gingival and frenum laceration is seen. Tooth 51 has been laterally luxated in a mesial position and is mobile. The parents were instructed to follow a careful tooth brushing technique. (b) The X-ray shows the displaced position of tooth. (c) Clinical appearance 9 days after trauma. The tooth is almost in its original position, has slight mobility and good oral hygiene is observed.



*Fig. 3.* Injuries to the developing teeth. An 8-year-old girl sought treatment because of delayed eruption of tooth 21. The history revealed that she fell three steps from the stairs while using the baby walker. Recommendations on oral hygiene and follow-up controls were given at the Emergency Room. Teeth 51 and 61 apparently were not affected and had normal resorption at the time of shedding. (a) Hypoplasia of tooth 11 affecting the incisal third of the crown. Crown dilacerations is seen in tooth 21. (b) Clinical appearance of tooth malformation affecting both central incisors: hypoplasia with loss of tooth structure in tooth 11 and delayed eruption is observed in tooth 21. (c) After completion eruption, crown dilaceration is seen in tooth 21.

injured tooth and the occlusion, are important factors that influence treatment selection.

#### Guidelines for the clinician

The Guidelines contain recommendations for diagnosis and treatment of traumatic injuries in the primary dentition for caries-free or sound primary teeth using proper examination procedures:

##### A. Clinical examination.

Information about examination of traumatic injuries in the primary dentition can be found in a number of current textbooks (1, 5, 10).

##### B. Radiographic examination

Depending on the child's ability to cope with the procedure and the type of injury suspected, several angles are recommended:

- 90° horizontal angle, with central beam through the tooth in question (size 2 film, horizontal view).
- Occlusal view (size 2 film, horizontal view).
- Extra-oral lateral view of the tooth in question, which is useful to reveal the relationship between the apex of the displaced tooth and the permanent tooth germ as well as the direction of dislocation (size 2 film, vertical view).

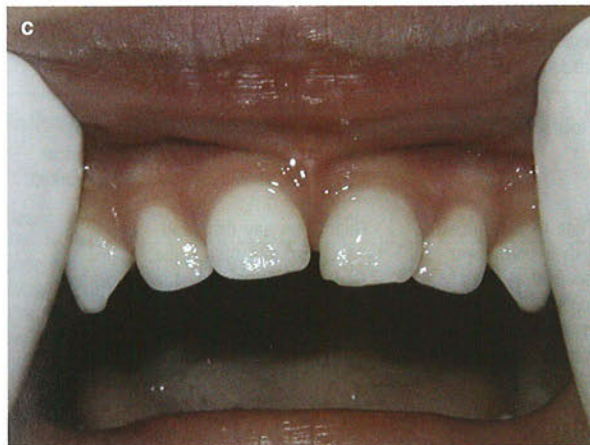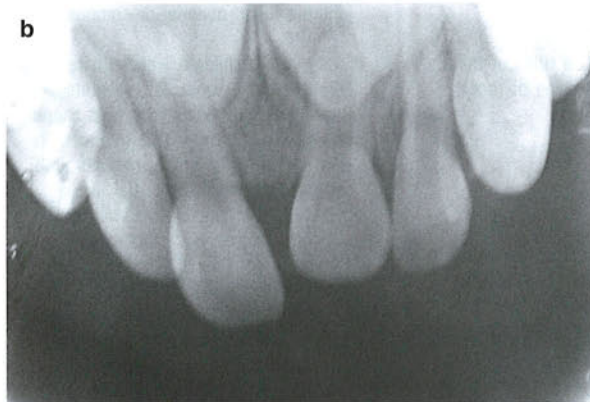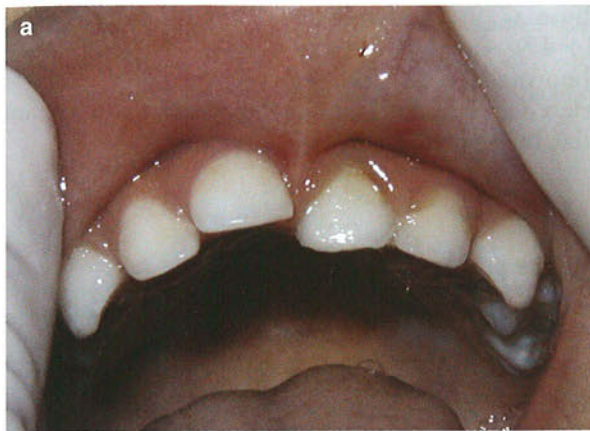##### C. Patient instructions

Good healing following an injury to the teeth and oral tissues depends, in part, on good oral hygiene. Parents should be advised on how best to care for their children's primary teeth after an injury. (Fig 4). Brushing with a soft brush after each meal and applying chlorhexidine (0.1%) topically to the affected area(s) with cotton swabs twice a day for one week, is beneficial to prevent accumulation of plaque and debris. Along with recommending a soft diet for 10–14 days, restrict the use of pacifier.

If there are associated lip injuries, use of lip balm during the healing period will avoid dryness.

Parents should be further advised about possible complications that may occur, like swelling, increased mobility or fistula. Children may not complain about pain; however, infection may be present and parents should watch for signs such as swelling of the gums and bring the children in for treatment.

Document in the chart that the parent has been informed about possible complications in the devel-



*Fig. 4.* (a) A 2 year and 6 month-old boy fell while he was jumping on the bed. The mother noticed that the left central incisor was displaced and sought emergency treatment immediately. Instructions on oral hygiene, including topical use of chlorhexidine gel using cotton swabs for one week, were given to the mother. Also, it was recommended a soft diet for 2 weeks along with restricting the use of pacifier. (b) An occlusal view at the time of injury shows an overlapping of the primary roots and the developing permanent incisors; however, it is possible to observe an apical increased periodontal ligament space. (c) Spontaneous reposition of tooth 61 at two and a half months follow-up control.

The child's maturity and ability to cope with the emergency situation, the time for shedding of the

opment of the permanent teeth, especially following intrusion, avulsion and alveolar fracture injuries sustained in children under 3 years of age.

For further reading we recommend some recent good review articles and original papers on child

abuse (7–9), epidemiology (11–13), pulp therapy (14–17), intrusive luxation (18, 19) and tooth abnormalities (20–22). All relevant new and old references can be found in the recent textbook and atlas by Andreasen et al. (1).

### Treatment guidelines for fractures of teeth and alveolar bone in the primary dentition

Clinical findings	Radiographic findings	Treatment
<b>Uncomplicated crown fracture</b>		
Fracture involves enamel or dentin and enamel; the pulp is not exposed.	The relation between the fracture and the pulp chamber will be disclosed.	Smooth sharp edges. If possible the tooth can be restored with glass ionomer filling material or composite.
<b>Complicated crown fracture</b>		
Fracture involves enamel and dentin and the pulp is exposed.	One exposure is useful to rule out the extent of fracture and stage of root development.	In very young children with immature, still developing roots, it is advantageous to preserve pulp vitality by pulp capping or partial pulpotomy. This treatment is also the choice in young patients with completely formed roots. Calcium hydroxide is a suitable material for such procedures. Both treatments should be considered whenever possible, otherwise extraction is indicated.
<b>Crown-root fracture</b>		
Fracture involves enamel, dentin and root structure; the pulp may or may not be exposed. Additional findings may include loose, but still attached, fragments of the tooth. There is minimal to moderate tooth displacement.	In laterally positioned fractures, the extent in relation to the gingival margin can be seen.	Treatment recommendation is tooth extraction. Care must be taken to prevent trauma to the subjacent tooth bud.
<b>Root fracture</b>		
The coronal fragment is mobile and may be displaced.	The fracture is usually located mid-root or in the apical third.	If the coronal fragment is displaced, extract only that fragment. The apical fragment should be left to be resorbed.
<b>Alveolar fracture</b>		
The fracture involves the alveolar bone. The tooth-containing segment is mobile and usually displaced. Occlusal interference is often noted.	The horizontal fracture line to the apices of the primary teeth and their permanent successors will be disclosed. A lateral radiograph may also give information about the relation between the two dentitions and if the segment is displaced in labial direction.	Reposition any displaced segment and then splint. General anesthesia is often indicated. Monitor teeth in fracture line.

### Treatment guidelines for luxation injuries in the primary dentition

Clinical findings	Radiographic findings	Treatment
<b>Concussion</b>		
The tooth is tender to touch; it has no increased mobility or sulcular bleeding.	No radiographic abnormalities. Normal periodontal space.	No treatment is needed. Observation.
<b>Subluxation</b>		
The tooth has increased mobility but has not been displaced. Bleeding from gingival crevice may be noted.	Radiographic abnormalities are usually not found. Normal periodontal space.	No treatment is needed. Observation.

Clinical findings	Radiographic findings	Treatment
<p><b>Extrusive luxation</b> The tooth appears elongated and is excessively mobile.</p>	Increased periodontal ligament space apically.	Treatment decisions are based on the degree of displacement, mobility, root formation and the ability of the child to cope with the emergency situation. For minor extrusion (<3 mm) in an immature developing tooth, careful repositioning or leaving the tooth for spontaneous alignment are acceptable treatment options. Extraction is the treatment of choice for severe extrusion in a fully formed primary tooth.
<p><b>Lateral luxation</b> The tooth is displaced, usually in a palatal/lingual direction. It will be often immobile.</p>	Increased periodontal ligament space apically is best seen on the occlusal exposure.	If there is no occlusal interference, as is often the case in anterior open bite, the tooth is allowed to reposition spontaneously. When there is occlusal interference, with the use of local anesthesia, the tooth can be gently repositioned by combined labial and palatal pressure. In severe displacement, when the crown is dislocated in a labial direction, extraction is the treatment of choice. If minor occlusal interference, slight grinding is indicated.
<p><b>Intrusive luxation</b> The tooth is usually displaced through the labial bone plate, or can be impinging upon the succedaneous tooth bud.</p>	When the apex is displaced toward or through the labial bone plate, the apical tip can be visualized and appears shorter than the contra lateral tooth. When the apex is displaced towards the permanent tooth germ, the apical tip cannot be visualized and the tooth appears elongated.	If the apex is displaced toward or through the labial bone plate, the tooth is left for spontaneous repositioning. If the apex is displaced into the developing tooth germ, extract.
<p><b>Avulsion</b> The tooth is completely out of the socket.</p>	A radiographic examination is essential to ensure that the missing tooth is not intruded.	It is not recommended to replant avulsed primary teeth.

**Follow-up procedures for traumatized primary teeth**

Time	1 week	2-3 weeks	3-4 weeks	6-8 weeks	6 months	1 year	Each subsequent year until exfoliation
Uncomplicated crown fracture			C				
Complicated crown fracture	C			C + R		C + R	
Alveolar fracture	C		S + C + R	C + R		C + R	(*)
Root fracture							
No Displacement	C	C + R		C + R		C(*)	
Extraction						C(*)	
Concussion/ Subluxation	C			C			
Lateral luxation Extrusion							
Spontaneous repositioning		C		C + R		C + R	
Intrusion	C		C + R	C	C + R	C + R	C(*)
Avulsion	C				C + R	C + R	C(*)

S = Splint removal; C = Clinical exam R = Radiographic exam.  
(\*) = Radiographic monitoring until eruption of the permanent successor

**References**

- Andreasen JO, Andreasen FM, Andersson L. Textbook and color atlas of traumatic injuries to the teeth, 4th edn. Oxford: Blackwell Munksgaard; 2007.
- Petersson EE, Andersson L, Sorensen S. Traumatic oral vs non-oral injuries. Swed Dent J 1997;21:55-68.
- Glendor U, Andersson L. Public health aspects of oral diseases and disorders: dental trauma. In: Pine C, Harris R, editors. Community oral health. London: Quintessence Publishing; 2007. p. 203-14.
- Glendor U, Halling A, Andersson L, Eilert-Petersson E. Incidence of traumatic tooth injuries in children and adolescents in the county of Vastmanland, Sweden. Swed Dent J 1996;20:15-28.
- Andreasen JO, Andreasen FM, Bakland LK, Flores MT. Traumatic dental injuries. A manual, 2nd edn. Oxford: Blackwell Munksgaard; 2003.
- Flores MT. Traumatic injuries in the primary dentition. Review. Dent Traumatol 2002;18:287-98.

7. Maguire SA, Hunter B, Hunter LM, Sibert J, Mann MK, Kemp AM. Diagnosing abuse: a systematic review of torn frenum and intra-oral injuries. *Arch Dis Child* 2007 [Epub ahead of print].
8. Cairns AM, Mok JY, Welbury RR. Injuries to the head, face, mouth and neck in physically abused children in a community setting. *Int J Paediatr Dent* 2005;15:310-8.
9. Serrano García MI, Tolosa Benedicto E, Forner Navarro L. Oral lesions due to child abuse. Identification of the problem and role of the professional. *Med Oral* 2001;6:276-89 (Article in English, Spanish).
10. Kramer PF, Feldens CA. Traumatismos na deinição decidua. Prevenção, Diagnóstico e Tratamento. Sao Paulo: Santos Editora Ltda; 2005.
11. Skaare AB, Jacobsen I. Primary tooth injuries in Norwegian children (1-8 years). *Dent Traumatol* 2005;21:315-9.
12. Borum MK, Andreasen JO. Therapeutic and economic implications of traumatic dental injuries in Denmark: an estimate based on 7549 patients treated at a major trauma centre. *Int J Paediatr Dent* 2001;11:249-58.
13. Kramer PF, Zembruski C, Ferreira SH, Feldens CA. Traumatic dental injuries in Brazilian preschool children. *Dent Traumatol* 2003;19:299-303.
14. Holan G. Long-term effect of different modalities for traumatized primary incisors presenting dark discoloration with no other signs of injury. *Dent Traumatol* 2006;22:14-7.
15. Raslan N, Wetzel WE. Exposed human pulp caused by trauma and/or caries in primary dentition: a histological evaluation. *Dent Traumatol* 2006;22:145-53.
16. Kupietzki A, Holan G. Treatment of crown fractures with pulp exposure in primary incisors. *Pediatr Dent* 2003;25:241-7.
17. Fuks AB. Current concepts in vital primary pulp therapy. *Eur J Paediatr Dent* 2002;3:115-20.
18. Spinass E, Melis A, Savasta A. Therapeutic approach to intrusive luxation injuries in primary dentition. A clinical follow-up study. *Eur J Paediatr Dent* 2006;7:179-86.
19. Gondim JO, Moreira Neto JJ. Evaluation of intruded primary incisors. *Dent Traumatol* 2005;21:131-3.
20. Sennhenn-Kirchner S, Jacobs HG. Traumatic injuries to the primary dentition and effects on the permanent successors - a clinical follow-up study. *Dent Traumatol* 2006;22:237-41.
21. Christophersen P, Freund M, Harild L. Avulsion of primary teeth and sequelae on the permanent successors. *Dent Traumatol* 2005;21:320-3.
22. Sleiter R, von AT. Developmental disorders of permanent teeth after injuries of their primary predecessors. A retrospective study. *Schweiz Monatsschr Zahnmed* 2002;112:214-9.

# Analysis of procedures used in tooth avulsion by 100 dental surgeons

Manfrin TM, Boaventura RS, Poi WR, Panzarini SR, Sonoda CK, Sundefeld MLMM. Analysis of procedures used in tooth avulsion by 100 dental surgeons.

**Abstract** – Accurate diagnosis and adequate treatment plan may constitute very complex tasks, particularly in tooth avulsion, because several variables are involved. In addition to the technical knowledge and clinical experience directed toward the quality of treatment, patient education may favorably influence the survival of replanted teeth. The aim of this study was to analyze the procedures used in the management of tooth avulsion by 100 dental surgeons (DSs). Thus, by means of a descriptive questionnaire, information was obtained about the profile of the professionals interviewed, procedures used in cases of tooth avulsion, and patient orientation and education. One hundred properly filled questionnaires were obtained. Descriptive statistics was used for the data, and the chi-squared statistics was employed (EPI-INFO 3.2 software). According to the results, this type of trauma is part of the routine of 15 DSs, although 71 have reported some experience with avulsed teeth. Great deficiencies were found regarding root surface treatment and occlusal adjustment. Positive findings were related to socket treatment, adjunctive therapy, and patient education and orientation (extra-alveolar period, storage medium, manipulation of the avulsed tooth, replantation by the own patient). It was possible to conclude that 47.5% of the procedures reported by 100 professionals interviewed are adequate, and patient education is favorable in 87.7% of cases, a fact that can positively interfere with the prognosis of tooth replantation.

Dental trauma has been gradually receiving epidemiological expression as an emerging public health problem (1, 2), as the caries prevalence is reduced with the preventive advances (3) and the increase in violence rates, as well as in the popularity of radical contact sports (2).

Within this context, there may be a simple enamel fracture up to tooth avulsion. Avulsions, in turn, should be emphasized because of the several factors involved, especially the prompt and proper initial care (4), besides long-term clinical and radiographic follow-up (5, 6). On the other hand, the integrity of the periodontal ligament, advocated by many as being essential for the success of replantation, cannot be controlled by the dental

professional, as it depends on the interaction of factors, such as extra-alveolar period, storage medium, and contamination of the avulsed tooth (7–10). In clinical practice, patients in need of replantation attend the office hours or days after the accident, with the tooth in their hands, pockets, or involved by paper, gauze, or cotton (11).

Moreover, tooth avulsion changes the dental routine, as the professional then needs to perform treatment plans different than usual (12), which may be a complex task. Combined to the re-establishment of esthetics and function, there is also the patient management from a psychological standpoint (13).

Studies conducted on lay individuals (parents, teachers, sport instructors, nurses, lifeguards) reveal

**Thais Mara Manfrin, Renata Santos Boaventura, Wilson Roberto Poi, Sônia Regina Panzarini, Celso Koogi Sonoda, Maria Lúcia Marçal Massa Sundefeld**

Araçatuba Dental School, Sao Paulo State University – UNESP, Araçatuba, São Paulo, Brazil

**Key words:** tooth avulsion; tooth replantation; knowledge; dental education

Wilson Roberto Poi, Department of Surgery and Integrated Clinic, Dental School, São Paulo State University – UNESP, Rua José Bonifácio, 1193, Vila Mendonça, Araçatuba, São Paulo, 16015-050, Brazil  
Tel.: +55 (18) 3636 3240  
e-mail: poi@foa.unesp.br

Accepted 15 August, 2005